

## Coexistence of generalized pustular psoriasis and bullous pemphigoid: Pathogenic relationship or coincidence?

Sultan Al-Otaibi, MD, Adel Al-Abdulrazzaq, MD, Nabeel Najem, MD

*Department of Dermatology, Adan Hospital, Kuwait*

### ABSTRACT

Psoriasis vulgaris and bullous pemphigoid represent two clinically well-characterized, chronic, inflammatory skin diseases. The concomitant occurrence of these two entities in a patient is rare, and the exact nature of this relationship is not clear. We describe a 31-year-old woman with a history of plaque-type psoriasis who presented with generalized pustular psoriasis after which she developed disseminated vesiculobullous lesions. Skin biopsies showed the typical histologic and immunohistochemical traits of bullous pemphigoid. Bullous pemphigoid is the autoimmune blistering disease that has most often been associated with psoriasis. The pathogenic relationship between psoriasis and bullous pemphigoid is unclear. It has been postulated that the autoimmune process responsible for bullous pemphigoid lesions may be induced by ultraviolet light therapy, topical corticosteroids, and/or the inflammatory processes that occur in psoriasis.

### INTRODUCTION

Psoriasis is one of the most common inflammatory skin diseases. Inflammatory processes and specific immunologic factors have been described in its etiopathogenesis. Bullous pemphigoid represents a distinct autoimmune disease in which the skin is the main target organ. The role of autoantibodies against basement membrane antigens is well established. The occurrence of psoriasis and bullous pemphigoid at the same time in the same patient has been described previously, but most of them presented with plaque type psoriasis. We describe a middle aged woman with the consecutive manifestation of pustular psoriasis and bullous pemphigoid.

### CASE REPORT

A 31-year-old female with a history of chronic plaque psoriasis since childhood, presented with

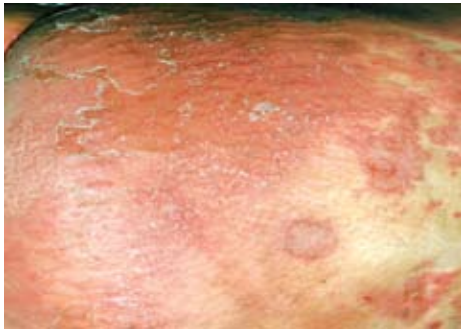disseminated pustular skin lesions associated with pruritus, chills and general malaise (Fig. 1). She was feverish and examination revealed pitting edema of the lower limbs. A complete blood count showed the following values: white blood cells,  $18.3 \times 10^9/l$  with 65.9% neutrophils, 12.6% lymphocytes, 2.6% monocytes and 18.9% eosinophils; hemoglobin 100 g/l and platelets  $462 \times 10^9/l$  and ESR 20 mm/hour. Serum biochemical profile was normal except for low total protein (45 g/l) as well as low albumin level (25 g/l). Histological examination of a skin biopsy revealed large spongiform pustules of Kogoj alongside acanthosis and dermal inflammatory infiltrate (Fig. 2).

The patient was treated with methotrexate and ceftriaxone as well as other topical and supportive measures, with the diagnosis of generalized pustular psoriasis and improved satisfactorily. Sixteen

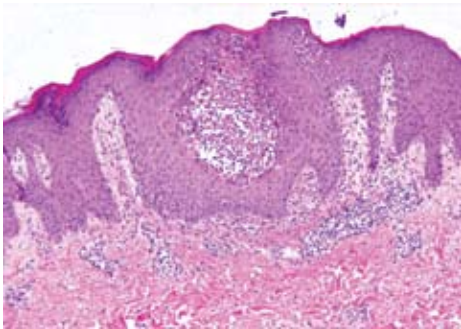
---

*Correspondence: Dr. Sultan Al-Otaibi MD, Department of Dermatology, Adan Hospital, Kuwait, E-mail: dralotaibi@hotmail.com*

days later, she developed tense vesiculobullous lesions on the trunk and extremities, sparing the



**Fig. 1** Disseminated pustular skin eruptions with confluent areas.

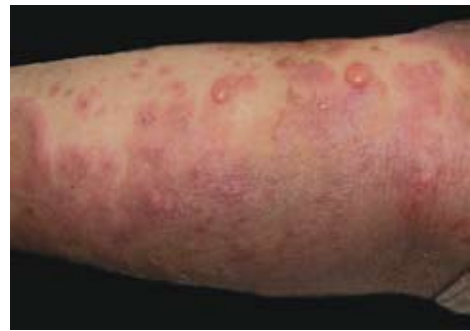

**Fig. 2** Large spongiform pustule of Kogoj, regular acanthosis as well as dermal inflammatory infiltrate (hematoxylin and eosin, x40).

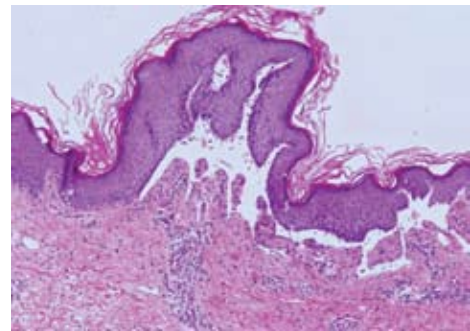
mucous membranes (Fig. 3). Histopathological examination revealed subepidermal bullae alongside dermal eosinophilic infiltrate (Fig. 4).

Direct immunofluorescence testing of perilesional skin showed strong linear IgG and C3 deposits along the epidermal basement membrane zone (Fig. 5). Indirect immunofluorescence studies revealed circulating anti-basement membrane zone IgG antibodies. Salt-split skin immunofluorescence studies revealed binding of pemphigoid antibodies to the blister roof. Furthermore, bullous pemphigoid antigen 180-kD (BPAg2) was found to be significantly high in patient's serum by enzyme-linked immunosorbent assay (ELISA). Methotrexate was discontinued and the patient

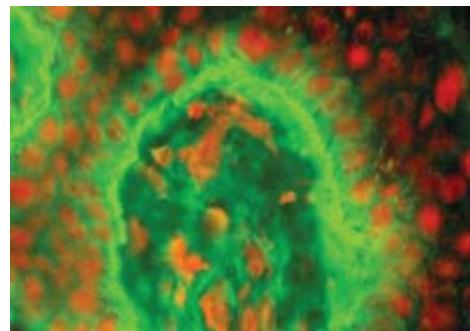
was started on dapsone as well as systemic glucocorticoid. The patient dramatically improved but developed dapsone induced hemolytic anemia. After the hemolytic crisis subsided dapsone was replaced by cyclosporine. The patient improved satisfactorily.



**Fig. 3** Clear, tense bullae on psoriatic plaque.



**Fig. 4** Subepidermal bulla and eosinophilic infiltrate at the tips of dermal papillae (hematoxylin and eosin, x40).



**Fig. 5** Direct immunofluorescence testing of perilesional skin showing strong linear IgG and C3 deposits along the epidermal basement membrane zone.

## DISCUSSION

The coexistence of psoriasis and autoimmune bullous diseases was described in the literature as early as 1929.<sup>1</sup> Amongst these blistering diseases, bullous pemphigoid has been reported most frequently. It is not clear whether the occurrence of psoriasis and acquired bullous diseases is a true pathogenic relationship or a mere coincidence.<sup>2</sup> Bullous pemphigoid is an autoimmune disease. Evidence is accumulating that psoriasis is also an autoimmune disease, suggesting that a common immunogenetic mechanism may be involved.<sup>3</sup> The common denominator in both diseases is the basement membrane. Apart from disease-related disruption of the basement membrane zone, different antipsoriatic treatments have been thought to cause altered antigenicity. It has been postulated that in psoriatic patients treated previously with PUVA and UVB, abnormal psoriatic epidermis during the treatment with UVB radiation induces production of BP autoantibodies in susceptible in-

dividuals.<sup>4</sup> This does not explain the appearance of BP in our patient for whom phototherapy was not used in the treatment of psoriasis. In summary, our patient with psoriasis and bullous pemphigoid shared features with those previously reported.<sup>2</sup> The etiopathogenic significance of the coexistence of these two entities remains unknown, and may be related to the relatively high incidence of both diseases, or may be a coincidence.

## REFERENCES

1. Bloom D. Psoriasis with superimposed bullous eruption. *Med J Rec* 1929; 130:246-8.
2. Wilczek A, Sticherling M. Concomitant psoriasis and bullous pemphigoid: coincidence or pathogenic relationship? *Int J Dermatol*. 2006 Nov; 45(11):1353-7.
3. Primka EJ, Camisa Ch. Psoriasis and bullous pemphigoid treated with azathioprine. *J Am Acad Dermatol* 1998; 39:121-3.
4. Perl S, Rappersberger K, Fodinger D et al. Bullous pemphigoid induced by PUVA therapy. *Dermatology* 1996; 193:245-7.